

## **Surgical management of morbidity due to lymphatic filariasis: The usefulness of a standardized international clinical classification of hydroceles**

Capuano, G.P.<sup>1\*</sup> and Capuano, C.<sup>2</sup>

<sup>1</sup>Ministry of Health, 88 Amy street, PO Box 2223, Government Buildings, Suva, Fiji

<sup>2</sup>World Health Organization, P.O. Box 12550, 50782 Kuala Lumpur, Malaysia

\*Corresponding author email: capuanop@gmail.com

Received 15 August 2011; received in revised form 12 September 2011; accepted 13 September 2011

**Abstract.** The objective of this work is to evaluate the usefulness of a standardized clinical classification of hydroceles in lymphatic filariasis endemic countries to guide their surgical management. 64 patients with hydroceles were operated in 2009-2010, in Level II hospitals (WHO classification), during two visits to Fiji, by the same mobile surgical team. The number of hydroceles treated was 83. We developed and evaluated a much needed clinical classification of hydroceles based on four criteria: Type (uni/bilateral); Side (left/right); Stage of enlargement of the scrotum rated from I to VI; Grade of burial of the penis rated from 0 to 4. It led to the conclusion that 1) A Stage I or II hydrocele, associated with Grade 0 or 1 penis burial could be considered a "Simple Hydrocele". The surgical treatment is simple with no anticipated early complication. WHO Level II of health care structure seems adapted. 2) A Stage III or IV hydrocele associated with Grade 2, 3 or 4 penis burial could be considered a "Complicated Hydrocele". The operation is longer, more complicated and the possibility of occurrence of complications seems greater. A level III health care facility would be more adapted under the normal functioning of the health system. We conclude that a standardized clinical classification of hydroceles based on the Stage of enlargement of the scrotum and the Grade of burial of the penis appears to be a useful tool to guide the decision about the level of care and the surgical technique required. We use the same classification for penoscrotal lymphoedema. A decision tree is presented for the management of hydroceles in lymphatic filariasis endemic countries which could usefully complement the "Algorithm for management of scrotal swelling" proposed by WHO in 2002. An international classification system of hydroceles would also allow standardization and facilitate study design and comparisons of their results.

### INTRODUCTION

Lymphatic filariasis is a major public health problem in many tropical countries (Gyapong *et al.*, 1998). In 2010, the World Health Organization (WHO) estimates that 1.34 billion people are living in filarial endemic countries, and are therefore at risk of infection. WHO also estimates that 120 million people are suffering from filariasis in 81 countries and that 40 million are showing clinical signs of the disease, including 25 million men suffering from its urogenital

manifestations (penoscrotal lymphoedema and hydrocele) (WHO, 2010).

These severe and progressive physical consequences can be particularly disabling considering the proportions they can reach. They also often result in psychological disorders which have a major impact on the social, professional and married life of the patient (WHO, 2002). Among the clinical manifestations targeted by the Global Programme for the Elimination of Lymphatic Filariasis, hydrocele or the accumulation of fluid in the tunica vaginalis is the one that

has received the least attention (Addis & Brady, 2007).

While an anatomic classification of pediatric hydroceles exists (Ortenberg *et al.*, 2009) we found in the literature no clinical or anatomic classification of hydroceles due to filarial infection, which are in many respects very different from the usually small hydroceles found in children. In the literature the subjectivity affecting the evaluation of the enlargement of the scrotum is illustrated by the variety of adjectives used to describe the size of the hydroceles: “small”, “big”, “large”, “very large”, “rather big”, “huge”, “monstrous” are the most commonly utilized with no reference to clinical measurements. For example Ahorlu *et al.* (2001) refer in the same interesting article to the size of hydrocele using the following words: “large”, “big”, “smaller” with no information on their translation into standardized measurements. The authors mention that hydrocele result in impairment on the physical activity and social life of the patients “especially in those with large ones.” This heterogeneity is confirmed by our experience in filarial endemic countries where health professionals would compare the hydrocele size to a “small papaya”, “a big papaya”, “a coconut” or a “huge watermelon” to quote only a few examples. Some authors reporting on sometimes important and impressive series never mention the size of the hydroceles treated.

The very useful reference “Surgical approaches to the urogenital manifestations of lymphatic filariasis” published by WHO (2002) refers to a multicentric study conducted in 1992-1995 in India, Africa and the Philippines comparing the size of the hydrocele and its relation to the acute disease. In this work hydroceles were classified in two groups depending on their size: lesser or greater than a tennis ball. Hydroceles smaller than a tennis ball were identified as “small hydroceles” while those bigger than a tennis ball are referred to as “large hydroceles.” In the literature even simple reference to the “size” of the hydrocele is confusing. Some authors (Ku *et al.*, 2001) will refer to it as a measurement of the quantity of fluid removed during surgery

while others will refer to its apparent size (Ahorlu *et al.*, 2001). The heteroclitic arsenal of words used to describe the clinical enlargement of the scrotum is a limiting factor when comparing the results of published series, sometimes reporting on impressive numbers of patients treated or on a long period of follow up. The assessment of the size of a hydrocele is left to the subjectivity of each observer.

It is therefore difficult to assess the importance of the size of the hydrocele and its impact on the surgical technique needed, the outcome of the surgery, the management of the patient, or the level of care required. The absence of a standardized classification of hydroceles leaves room for subjectivity and makes comparisons and guidance difficult. It might be a contributing factor to the multiplicity of surgical techniques used and highlighted by Noroes & Dreyer (2010). Considering this vacuum it became clear to us that the development of a clinical classification of hydroceles in lymphatic filariasis endemic countries would not only be useful for the management of the patients and the surgical treatment but that it was also necessary to allow comparison of results at international level.

For the enlargement of the scrotum we chose a classification which is simple, accessible to all and rational as it is based on bony landmarks, the only ones that are fixed and can be used regardless of the morphology of the patient. We evaluated its relevance and usefulness in the decision process of the surgical management of hydroceles during two visits to the Fiji Islands in 2009 and 2010 as part of a small mobile surgical team focusing exclusively on surgical treatment of hydroceles. Patients were identified during the preliminary phase using an innovative and an active detection process by a trained and mobile nurse practitioner. This process is part of an original project aiming at the detection and management of morbidity due to Lymphatic Filariasis in the Pacific which was verbally presented by one of the authors at the 2009 and 2011 meetings of the Pacific programme managers organized by WHO (2011).

## PATIENTS AND METHODS

### Patients

A preliminary work using an original and active detection process registered the first 170 patients with hydrocele in the Fiji islands. The first two visits in November 2009 and from September to November 2010, allowed the observation and clinical classification of 65 patients. One patient was refused by the anesthetist, bringing to 83 the number of hydrocelectomy performed in 64 patients treated. The youngest patient was 16 years old, the oldest 70 years. The average age was 47 years. Fifty three out of the 64 patients (82.80%) were aged 21 to 60 years and over half were between 41 and 60 years. It was sometimes difficult to know the age of the patients as many of them did not know their date of birth. It would have been interesting and probably useful to know precisely the age of these hydroceles. Unfortunately the information provided by the patients should be taken with caution; they either do not know, or they give unrealistic figures. Subject to this, if we use the information provided, the age of evolution of hydroceles treated in our series ranged from 1 to 40 years, with an average of 9 years.

### Method

Each hydrocele was classified using four clinical criteria. The additional information described below was also collected. In this initial work the classification of the hydrocele was not considered to guide the decision about the surgical procedure performed. The need to do a simple closure of the scrotum ("simple hydrocele") or to do a reduction of the scrotum by plasty and/or a surgical reduction of buried penis ("complex hydrocele") was made by the surgeon during the operation, after the complete removal of the sac. The detailed procedure was recorded for each patient. All the information gathered was entered and analyzed using an Excel database.

### Clinical classification of hydroceles

The hydroceles recorded in this work were all classified by the operating surgeon himself in the immediate preoperative period

or the day before surgery, based on their clinical appearance on the standing patient and if possible already prepared with shaving. We used four clinical criteria:

#### 1) **Type of hydrocele**

Unilateral or bilateral.

#### 2) **Side of hydrocele**

Right or left side of the scrotum

For each *bilateral* hydrocele we recorded: a *right* side hydrocele and a *left* side hydrocele.

#### 3) **Size of hydrocele**

Hydroceles were classified according to their size into six stages. The stages are recorded in roman numerals.

- *Stage I*: The size of the scrotum is less than that of a tennis ball. FIGURE 1
- *Stage II*: The size of the scrotum is greater than that of a tennis ball up and down; the lower pole of the scrotum does not reach halfway up the thigh (between the lower edge of the great trochanter and the top edge of the knee identified by the upper edge of the patella). FIGURE 2
- *Stage III*: The lower pole of the scrotum goes down to mid-thigh and reaches the area between mid-thigh and the knee (upper edge of the patella). FIGURE 3
- *Stage IV*: The lower pole of the scrotum reaches the area between the upper edge of the patella and the lower edge of the knee (tibial tuberosity). FIGURE 4
- *Stage V*: The lower pole of the scrotum reaches the area between the lower edge of the knee (tibial tuberosity) and mid-leg. FIGURE 5
- *Stage VI*: The lower pole of the scrotum reaches the area between mid-leg and the ankle (bi-malleolar line). FIGURE 5

#### 4) **Burial of the penis**

The burial of the penis, which often accompanies hydroceles, can be assessed on the patient standing or lying down. The burial was classified according to its

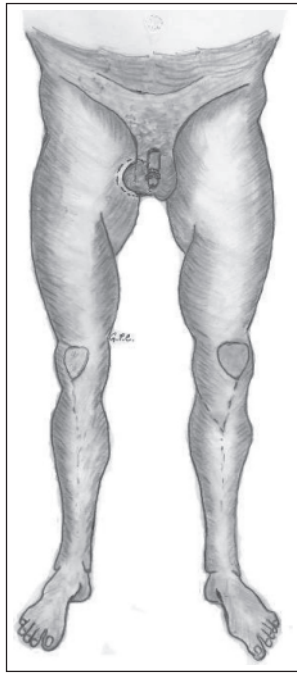


Figure 1. Stage I

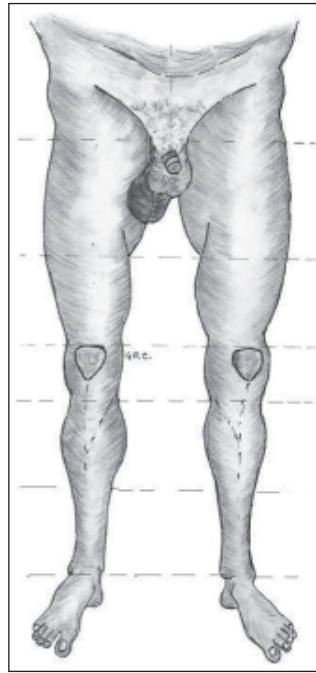


Figure 2. Stage II

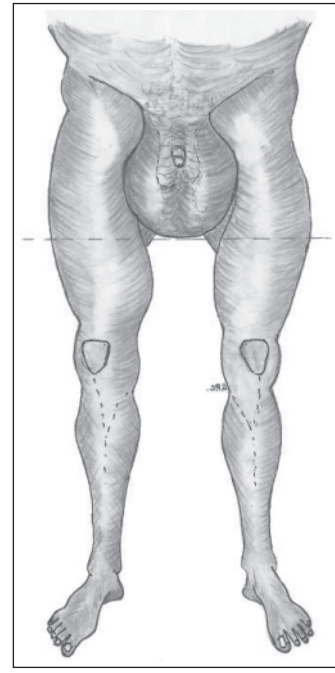


Figure 3. Stage III

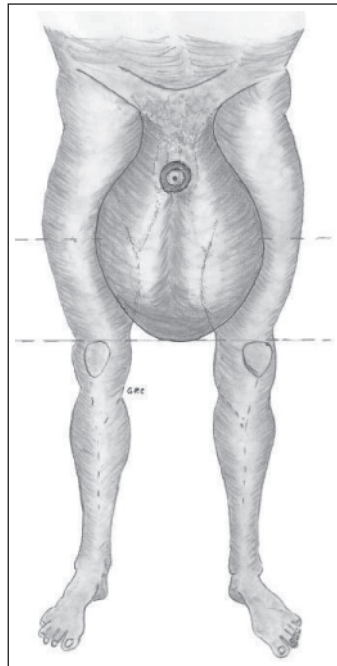


Figure 4. Stage IV

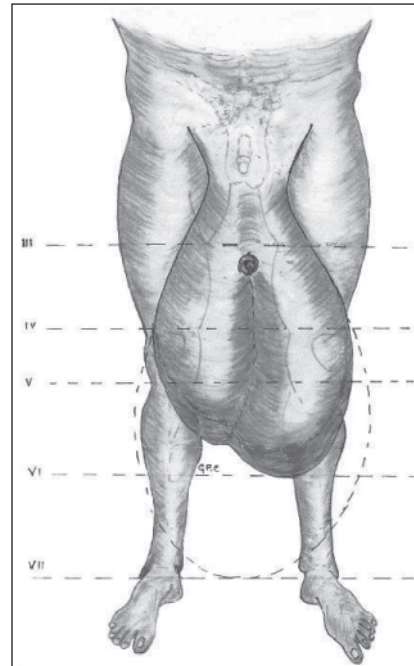


Figure 5. Stages V and VI

importance, in five categories or Grades from zero to four recorded in arabic numerals:

- *Grade 0*: no apparent burial, the length of the penis is within normal limits. FIGURE 6
- *Grade 1*: partial burial, the length of the visible part of the penis is *more* than 2cm. FIGURE 7
- *Grade 2*: more important partial burial, the length of the visible part of the penis is *less* than 2cm. FIGURES 8a and 8b.
- *Grade 3*: total burial of the penis. The prepuce, or the tip of the glans penis if the patient is circumcised, is visible and flush with the surface of the scrotum FIGURE 9

- *Grade 4*: total burial of the glans penis which is invisible, the burial cannot be reduced and causes micturition problems FIGURE 10

## 2.2. Other information recorded

In addition, during and after surgery we collected the following information for each patient treated:

- Amount of liquid removed: with the syringe (for the laboratory) and by suction (for full emptying);
- Liquid appearance: citrine, chocolate or milky;
- Presence or absence of debris in the liquid;

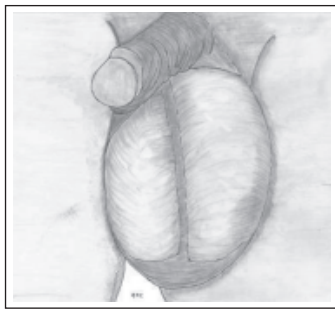


Figure 6. Grade 0

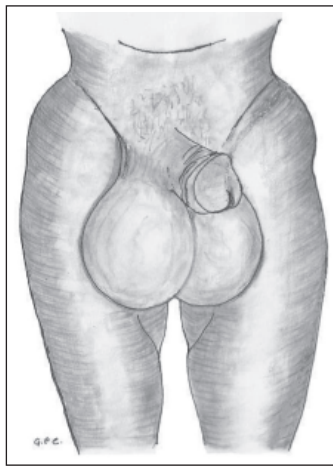


Figure 7. Grade 1

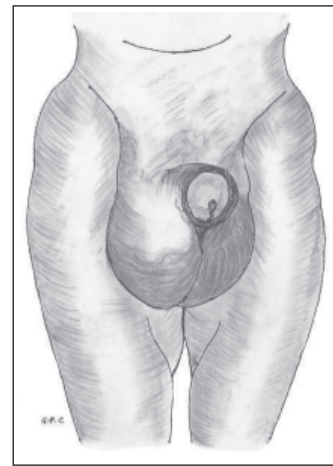


Figure 8a. Grade 2 (Face)

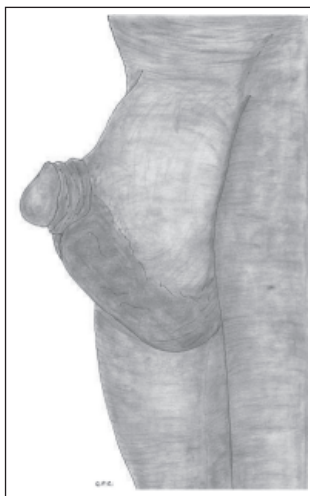


Figure 8b. Grade 2 (Profile)

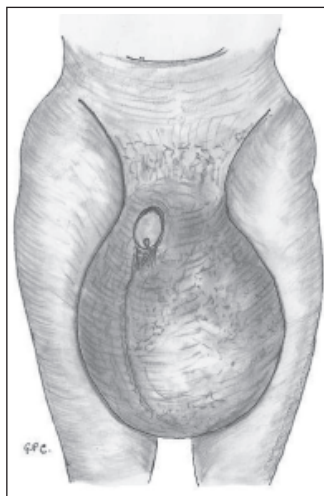


Figure 9. Grade 3

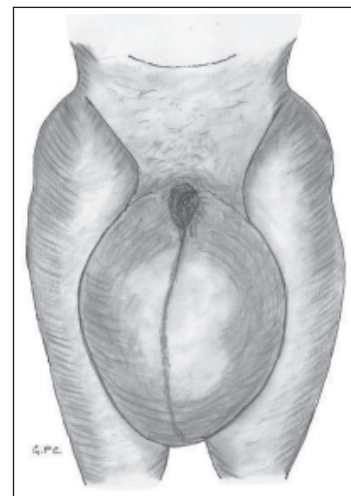


Figure 10. Grade 4

- Complementary treatment: excision of epididymal cysts, hydatids or other associated conditions discovered during the surgical treatment of the hydrocele;
- Treatment of the scrotum: by simple closure or by personal technique of scrotal reduction by plasty.
- Reduction of a burial of the penis: spontaneous during surgery or by surgical treatment;
- Type of anesthesia: spinal anesthesia or general anesthesia.
- Content emptying by electric suction.
- Complete vertical opening of the vaginalis on its front side by electrocautery knife from the drain suction hole to the lower pole at the level of the handle of the deferent and then up until the cord.
- Inventory and examination of the testis and epididymis.
- Removal of related lesions by electrocautery knife: hydatids, cysts of the head or of the tail of the epididymis.

We also recorded the length of stay of patients and the postoperative complications, their type and the management they required.

### 2.3. Anesthesia, surgical technique, postoperative dressing and follow up

The fasting patients were hospitalized the day before or the morning of the surgery for clinical, biological and electro-cardiographic assessment and usual preparation (shaving of the designated surgical area, shower).

With the exception of four patients who received general anesthesia immediately or after a spinal anesthesia, all patients had a spinal anesthesia.

All hydroceles were treated by total vagnalectomy using the following technique:

- Access: anterolateral right (for unilateral right hydrocele) or anterolateral left (for unilateral left hydrocele) or anterolateral right and left separately (for bilateral hydrocele).
- Section of the different layers under the scrotum with the electrocautery knife accompanied by a step-by-step electrocautery for perfect hemostasis.
- Identification of the spermatic cord as high as possible to the root of the scrotum and isolation.
- Externalization of the mass after complete dissection by fingers, electrocautery knife and Metzenbaum scissors.
- Fluid sample taking by needle and syringe for the laboratory.
- Complete resection of the parietal layer of the tunica vaginalis by electrocautery knife as close as possible to the path of its continuation as the visceral layer.
- Haemostatic cuticular suture on the cut margin on the periphery of the testis using absorbable sutures 000.
- Fixation of the testis to the lower pole of the scrotum (or the neo-scrotum if the patient had a scrotal reduction by plasty, see below).
- Closing in two layers on Delbet drain (corrugated rubber blade)
- Use of non-absorbable sutures for ligatures and suture of the deep layers and of the skin in a second time.

In a number of cases the importance of the excessive scrotum after treatment of the hydrocele justified a reduction by plasty. Similarly, in some instances the burial of the penis was not spontaneously reduced during the operation and a surgical reduction was performed. Both procedures were made using our own techniques. Such operations are more complex and longer than the “simple” procedure described above. We therefore recorded the treatment of the scrotum as being a “simple closure” (no plasty needed) or a “closure after reduction of the scrotum by plasty”. With the exception of the first nine patients, all benefited from a compressive and suspension dressing from our original design which will be presented in a separate publication. Starting from the tenth patient, all received postoperative antibiotics and

anti-inflammatory drugs. The drugs used varied depending on the availability in the four subdivisional hospitals where we worked. The duration of antibiotic and anti-inflammatory therapy was 6 days, including four days (whenever possible) during hospitalization.

## RESULTS

During the two visits and in the four hospitals which received our surgical team, 65 patients were registered in our series. One patient had been refuted by the anesthetist bringing to 64 the number of patients who underwent a hydrocelectomy. The postoperative course was uneventful in most cases. We only recorded 3 immediate complications, which are studied below. The results were excellent in all cases, including from an aesthetic point of view after scrotal reduction with or without a plasty of buried penis.

### **Type of hydroceles:**

Forty-five (71%) hydroceles were unilateral and 19 (29%) bilateral, representing a total of 83 hydroceles treated.

### **Side of hydrocele:**

We registered 48 or 57% hydroceles of the left side and 43% of the right side.

### **Size of hydroceles:**

77% of hydroceles were at an advanced stage: Stages III and IV of our classification. Stage III was predominant on the right side while

Stage IV was more often found on the left side FIGURE 11.

In this series we did not record any hydrocele of Stage V or Stage VI but in the literature and in reference books we identified cases that could be classified as such stages.

We found a few patients (not recorded in this series) with penoscrotal lymphoedema corresponding to Stage V of our classification that we also apply to penoscrotal lymphoedema.

### **Burial of the penis:**

47 (72.30%) patients had no burial of the penis (Grade 0), 1 patient had a Grade 1 burial (1.50%), 8 Grade 2 (12.30%), 7 Grade 3 (10.80%) and 2 Grade 4 (3.10%).

### **Surgical technique for the closure of the scrotum according to type/side of the hydrocele**

40% of unilateral hydroceles necessitated a closure of the scrotum by plasty-reduction compared to 29% for bilateral hydroceles.

In 33% of the right side hydroceles we closed the scrotum after scrotal reduction by plasty compared to 42% for left side hydroceles.

### **Surgical technique for the closure of the scrotum according to Stage** FIGURE 12

100% of Stage I and Stage II hydroceles lead to a simple closure of the scrotum.

For Stage III, 60% of the cases had a simple closure compared to 41% only for those with a Stage IV hydrocele.

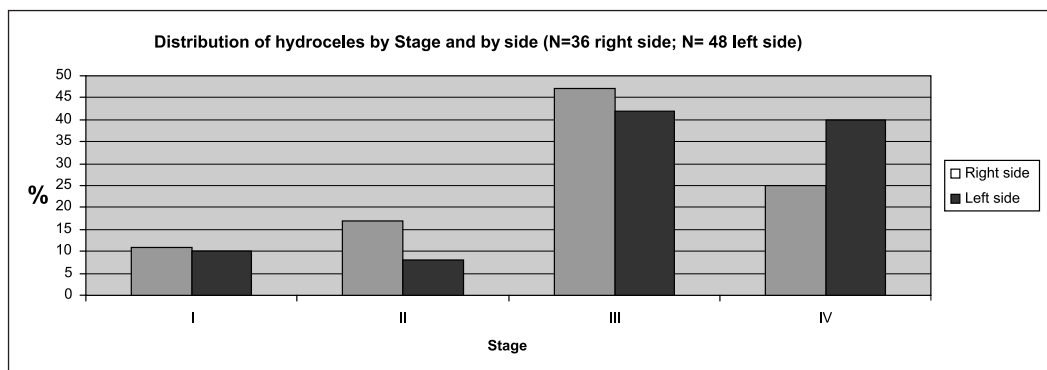


Figure 11. Distribution of hydroceles by Stage and by side

A reduction of the scrotum by plasty using our own techniques was necessary in 40% and 59% of cases at Stages III and IV respectively.

**Spontaneous and surgical reductions of buried penis according to Grade**  
**FIGURE 13**

Of the 18 cases of buried penis recorded, 100% for the first Grade of our classification were reduced spontaneously during surgery, against 57% and 56% respectively for Grades 2 and 3.

At Grade 4, 100% of the cases warranted a surgical reduction of the burial by plasty.

**Complications**

Of the 83 hydroceles treated we recorded 3 postoperative complications which

represent a complication rate of 3.60%. These complications are described below.

- A hematoma on partial dehiscence of the scar on 3 centimeters. It can be attributed, at least partially, to a suture by separated and maybe too tight knots, using the too thin nylon suture available. It was in a 70 year old patient with Stage IV left side hydrocele and Grade 3 burial of the penis. The hydrocele was complicated by a chylocele with inflammatory adhesions of the vaginalis. This patient also underwent a complementary unilateral plasty for a scrotal reduction by upper flap. He did not benefit from an antibiotic treatment and from the original dressing we developed and mentioned above.

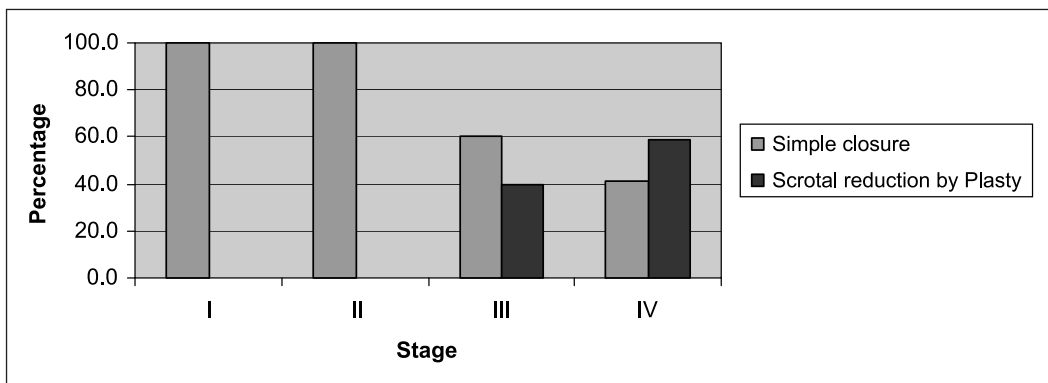


Figure 12. Surgical technique of closure of the scrotum by Stage

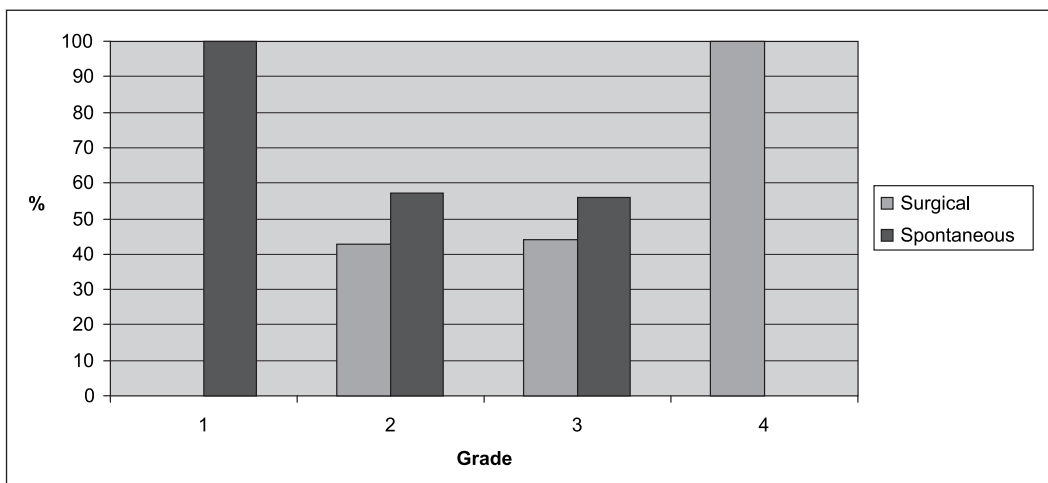


Figure 13. Reduction of the burial of the penis by Grade



- A hematoma in a 30 years old patient operated for a unilateral right hydrocele of Stage III and Grade 1, complicated by a hematocele with abundant debris. The dissection of the vaginalis had to be performed “vaginalis open” in situ without externalization of the mass. This dissection was made impossible by the vaginalis adhesions to the fiber layer. The patient benefited from a complementary anterolateral reduction of the scrotum by plasty by bottom flap. He did not receive a compressive dressing and an antibiotic treatment.
- A hematoma with small intermittent bleedings on a partial dehiscence of the scar in a 70 years old patient after hydrocelectomy for a bilateral hydrocele Stage IV on both sides with Grade 1 burial of the penis, complicated by a chylocele. Hydrocelectomy complemented with a wide bilateral scrotal reduction by bilateral plasty using a personal surgical technique. Bleeding during surgery justified a postoperative transfusion of 2 units of blood. This patient received a compressive dressing and antibiotic treatment.

These complications were treated by debridement, cleaning, excision of the mortified tissue, pack in the first; drainage in the last two patients. All three had simple and rapid healings with antibiotics and daily dressings.

All other patients had a remarkable and simple healing with no fever during their entire hospital stay, from two to six days, with an average stay of 3.5 days.

#### **Other information collected**

The amount of fluid removed by syringe followed by suction varied from 25 ml to 2400 ml with an average of 329 ml on the right side and 432 ml on the left side. In 79% of the cases the liquid was citrine; in 18% of the cases it was chocolate-colored and in 4% it was milky in appearance. In 7 cases we found cruoric

debris either free in the liquid or adhering to the parietal layer of the vaginalis.

In 15 cases we completed the treatment of the hydrocele by a complementary procedure: excision of cysts of the epididymis, hydatids or other associated conditions discovered during the surgical procedure.

#### **DISCUSSION**

It is important to keep in mind that our series is homogeneous:

- 1) by the method used for the identification and recruitment of the patients during the years 2008 and 2009;
- 2) by the level of health facilities we used for the surgical treatment of the hydroceles (subdivisional hospitals without an active surgical department, corresponding to Level II of the WHO classification);
- 3) also and above all, because all patients were managed by the same mobile surgical team during two visits, over a total period of 3 months of intervention (65 days of operation).

This point seems important because this homogeneity (especially the same surgeon for all observations and all surgical procedures, and same anesthetist) brings consistency, thus greater credibility to the results. This situation allows some preliminary conclusions that cannot be discussed for example for reasons of multiple stakeholders, structures of care or different operating techniques.

#### **Need for surgery**

A hydrocele in a lymphatic filariasis endemic country warrants a radical treatment by total vaginectomy by electrocautery whatever its size and the material conditions are. This implies that electricity should be available on site to surgical mobile teams during mass campaigns. In our series of 83 hydrocelectomy, 77% were at an advanced

stage: Stages III and IV of our classification. Such cases warrant surgical intervention. The remaining 23% were divided into Stages I and II (11% and 12% respectively). In these cases, surgical treatment was justified either because of their association with a contralateral Stage III or Stage IV hydrocele (nearly 50% of all cases), or by principle, because in the absence of any medical treatment, a filarial hydrocele can only evolve towards worsening (increase in volume and complications) and will warrant a surgical procedure. Moreover, as discussed below, the advanced Stages (III and IV) resulted in our series in more complicated procedures, making these cases more prone to complications. This justifies a surgical treatment even at an early stage. Moreover, Noroes & Dreyer (2010) demonstrated the risk posed by chronic filarial hydrocele for the integrity of the testis, even if in “small volume cases.” In all cases in our series the surgical treatment at hospital with admission for a few days, was necessary.

#### **Clinical usefulness of the classification and of its four components**

Our research and an extended study of an extensive bibliography on hydroceles did not find any mention of a clinical classification of hydroceles in filarial endemic countries. Some authors refer to the quantity of the fluid removed during the surgery (Ku *et al.*, 2001; Thomas *et al.*, 2009) but this is a per-operative observation and they do not draw conclusion on the usefulness of this finding in regards to a classification or the management of the patient.

A multicentric study conducted between 1992 and 1995 (WHO, 2002) aiming at assessing the relation between the size of the hydrocele and the acute disease compared the size of the hydrocele to the one of a tennis ball and used it as a criteria for repartition of the cases in two categories only: lesser or greater than a tennis ball. Such enlargement of the scrotum described as “monstrous” by an observer, will be only the size of a “big orange” (or papaya) for another observer who will distinguish it from a “small” or “medium orange”(or papaya), which is not more accurate. It is clear that in a tall patient (and

Fijians are tall or very tall) the length of a “half thigh” or a “half leg” will be different from that of a small or very small height patient. Thus, a hydrocele the size of a “tennis ball” will appear clinically much bigger in a small height male than in a giant. However, it remains that the size of the hydrocele proportionally to the size of the individual will result in the same handicap and should lead to the same management and treatment.

In our classification we use components which are clearly defined and easy to assess through a simple clinical examination even in a remote location and by a basically trained health worker. In addition, the four criteria we use cover the main clinical aspects of a hydrocele: type (uni or bilateral), side (left or right), size rated in Stages using well-known and easy-to-identify bone landmarks, and Grade of burial of the penis using observation alone and simple measurements. All these components can be easily measured by a wide range of health workers and professionals including at peripheral level. The hydrocele classification that we are offering fills an evident gap in the description of the clinical pictures presented by the patients. It provides a way to standardize the clinical observations, thus allowing fair comparisons of outcomes between series. A clinical classification system would have been useful in harmonizing findings and conclusions from former studies such as the evaluation of the consequences of hydroceles by Gyapong *et al.* (2000) or Ahorlu *et al.* (2001) on the psychological life, physical activity and social life of patients. It is likely that the perception and the impact of hydrocele vary depending on its clinical dimensions. The same rational applies to the penoscrotal lymphodema for which we use the same classification.

#### **Usefulness of the clinical classification to evaluate the appropriate level of health care facility**

100% of cases at Stages I and II benefited from a simple closure of the scrotum, without reduction by plasty compared to 60% at Stage III and 41% at Stage IV. The reduction of the scrotum by plasty using our reduction techniques is a more complex and hence a

longer procedure than a simple closure of the scrotum. These findings seem to indicate that the greater the enlargement of the scrotum (Stages III and IV), the more lengthy and complex the surgical technique may be, requiring a more comprehensive health care structure and a more experienced surgeon than cases of Stage I and Stage II. Under the normal functioning of the health system, where cases are detected in the periphery and referred to other levels, this can mean that complicated hydroceles should be treated in divisional or teaching hospitals (level III of the WHO classification), while cases of Stages I and II could be referred to less comprehensive health care structures (level II). It is noteworthy that in our series all cases were operated in Level II structures, without posing any particular problem. We attribute these results to the high level of specialization of our team consisting of an experienced surgeon used to surgery in sometimes difficult conditions and a confirmed anesthesiologist, both helped by highly experienced nurses. Hydrocelectomy for filarial hydrocele can not be performed on an outpatient basis under local anesthesia or block, as reported in sometimes larger series by the number of hydroceles treated but often dealing with idiopathic hydroceles with clear fluid and a soft vaginalis (Shah *et al.*, 1992).

#### **Usefulness of the clinical classification to evaluate the predictable difficulty of the intervention**

##### Stage criteria (size of the hydrocele)

In our series, we could perform a simple closure of the scrotum in 100% of cases of Stage I and Stage II. On the other hand 40% of Stage III cases and 59% of Stage IV cases needed a reduction of the scrotum with plasty, which is a much longer and more complicated (more bleeding) technique, thus more prone to complications. Indeed, we noted that the three hematoma including an infected one, occurred in those with Stage III or Stage IV hydroceles, and that these three hydrocelectomy were accompanied by reduction of the scrotum with plasty. We reported earlier that the first two postoperative complications occurred among the initial nine patients

treated, who did not benefit from our compressive dressing and from the antibiotic coverage and whose scrotum had been closed by interrupted sutures with the too thin and too cutting nylon suture made available to us.

##### Grade criteria (burial of the penis)

Regarding the burial of the penis, of the 18 cases, all Grade 1 had spontaneous reduction of the burial during surgery. In contrast at Grade 4, we found no spontaneous reduction of the burial and a complementary plasty was necessary for all cases. For Grades 2 and 3 the reduction was not always spontaneous or was incomplete in 43% and 44% of cases respectively. Based on these initial results, the surgical treatment of the burial of the penis is therefore to be considered in approximately 45% of cases of Grades 2 and 3, which adds to the duration of the intervention.

##### Type and Side criteria

While we could identify some apparent patterns linked to the hydrocele size and the burial of the penis and the difficulty and length of the intervention, no such observation could be made for these two other components of our classification. However, we note that in some cases, the need for an asymmetric anatomical reconstruction of both sides of the scrotum with the left testicle lower than the right one, can lead to an asymmetric resection of the two sides of the scrotum. Information on type and side of the hydrocele are interesting for epidemiological and anatomic-pathological purposes. However, the type and the side of the hydrocele do not seem to affect the duration or type of surgery needed.

On the contrary, the *Stage* of enlargement of the scrotum and the *Grade* of burial of the penis in the proposed classification seem very useful in *evaluating the anticipated difficulties during the intervention and its approximate duration (up to 2:30)*. We therefore believe it is useful to retain and use these two criteria for the clinical classification of hydroceles and referral to the most appropriate health facility. This classification, *based solely on clinical*

*observation*, allows a standardization of cases. In addition, it could easily be used at peripheral level for national screening programmes aiming at the detection of hydroceles, allowing patients' referral to the team and the level of health care adapted to the anticipated difficulty of the surgical treatment. This clinical classification may complement the "Algorithm for management of scrotal swellings" proposed by WHO (2002).

It is important to keep in mind that we report here hydrocelectomy in lymphatic filariasis endemic countries which are often developing countries facing various challenges such as a limited number of hospitals and shortage of health professional. Thus,

- A Stage I or Stage II hydrocele with a positive transillumination test, combined with a Grade 0 or 1 of penis burial could be considered a "simple hydrocele". The surgical treatment is simple and quick with no anticipated complication. WHO Level II of health care facility seems to be adequate for the purpose.
- A Stage III or Stage IV hydrocele, regardless of the outcome of the transillumination test, combined with Grade 2, 3 or 4 of penis burial could constitute a "complicated hydrocele". The term "complicated" refers here to the predictable operating difficulties and not to an anatomic-pathological complication of the hydrocele (haematocele, pyocele, etc). The operation is longer, more complicated (a scrotal reduction with plasty may be required), the possibility of occurrence of complications is greater, a level III health care facility seems to be more adapted.

The same principle can apply in mass campaigns where surgical treatment of hydroceles that warrant additional reduction of the scrotum or « scrotomectomy » can not be done under local anesthesia or block by a surgeon in training or a nurse practitioner.

Such surgical techniques can not be conducted on an outpatient basis. The complication rate, rather low in our still limited series, supports our conclusions.

#### **Usefulness of the clinical classification to standardize cases at international level**

Hydroceles in lymphatic filariasis endemic countries are very different from pediatric hydroceles, not only in volume but also by their anatomic-pathological development, their associated complications and their impact on the family and social life of affected males. The literature we reviewed for this work shows that the surgical techniques performed (more often used for traumatic or idiopathic hydroceles) differ significantly and substantially depending on the operator and not on the clinical presentation. We found no classification suitable for hydroceles in lymphatic filariasis endemic countries, which would guide the patient's referral and the surgical management process. The interest of the proposed classification of hydroceles in filarial endemic countries, which can probably be improved, cannot be overlooked. Its usefulness will be in tropical or subtropical countries where peripheral hospital infrastructure is still in development. Obviously, such a clinical classification will also be useful in multicentric studies as it standardizes the way to assess the size of hydroceles, allowing a fair comparison of the results.

The main aim of the present work is to contribute to the planning of the surgical management of hydroceles based on a simple clinical classification, understandable and applicable even by nurses and nurse practitioners working in isolated areas. Our work seems to argue in favour of a relationship between the clinical presentation of the hydrocele and the type of surgery needed. The secondary objective is to stimulate a discussion on the need to fill the important gap due to the lack of a common language on this neglected topic. Noroes & Dreyer (2010) highlight the difficulty in comparing studies due, among other factors,

to the multiplicity of criteria used, the diversity of techniques performed or the type of study. We are of the opinion that the absence of an agreed international classification system add to the confusion pointed out by the authors. The adoption of an international clinical classification of hydroceles in lymphatic filariasis endemic countries would allow the design of comparable studies and statistics, which are useful and necessary for public health programs.

Finally, based on our findings, we believe we can offer the following decision tree for the management of hydroceles in lymphatic filariasis endemic countries. FIGURE 14. Following the review of the results of

experiences from various countries, WHO (2002) proposed an algorithm for the management of scrotum swellings relying mainly on their cause (hydrocele vs. other cause than hydrocele). We believe that the decision tree we propose for the management of hydrocele, based on simple clinical findings, can usefully complement this algorithm.

#### Limitations of our work

We intervened in the context of a mobile, specialized and homogeneous team in terms of stakeholders. This could be considered a limitation. It would have been useful to test this clinical classification under the normal functioning of the health system to assess its

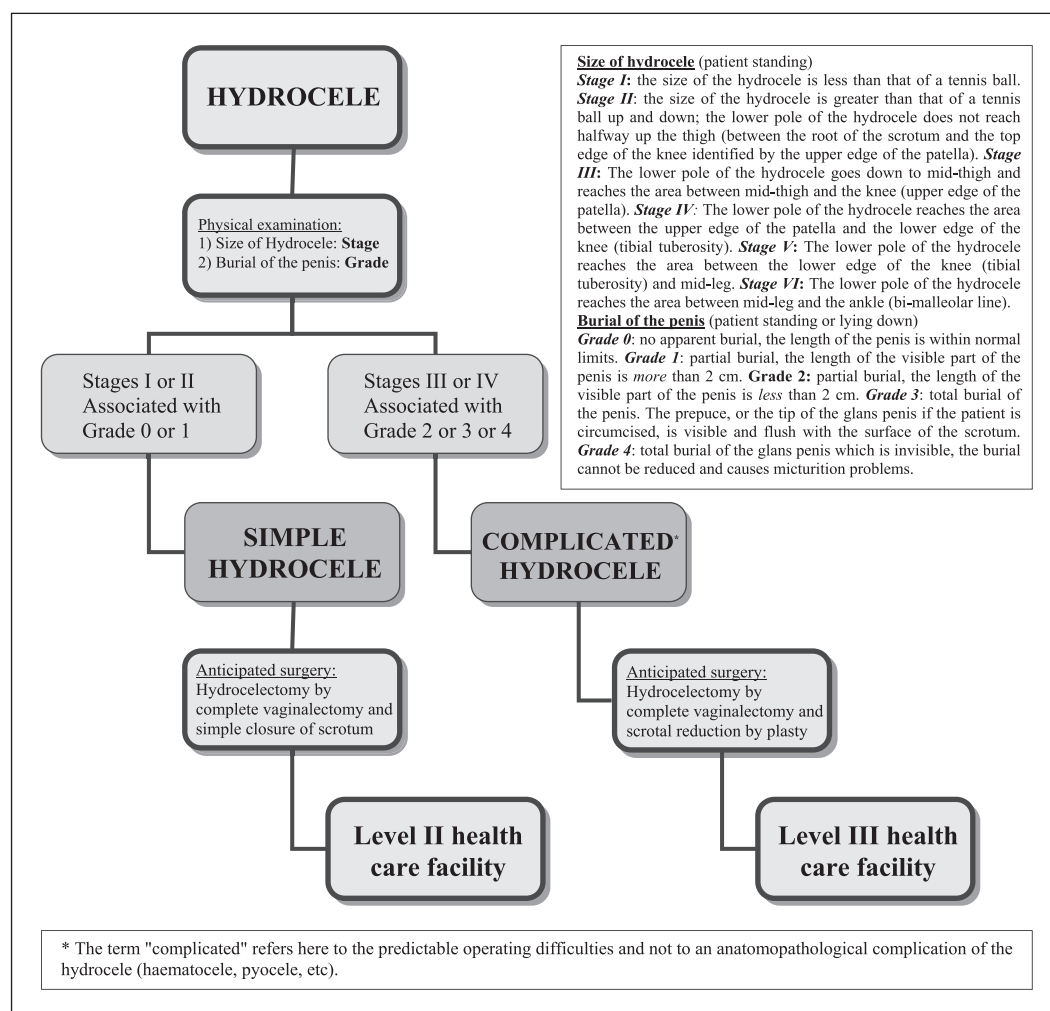


Figure 14. Decision tree for the surgical management of hydroceles in lymphatic filariasis endemic countries

effectiveness and adaptability in terms of patients' referrals to the appropriate level of care. Indeed, in our series, all patients have been examined and all hydroceles have been classified by the same operating surgeon. The proposed clinical classification needs to be tested by nurse practitioners and by health centers staff to whom it is obviously primarily intended. It is part of the next step of this study.

Another limitation is the small number of complications (3) compared to the number of hydroceles treated (83) which does not allow us to draw any conclusion on this matter. To possible remarks on the number of patients treated in this series (64) compared to sometimes more important ones in this regard, which is something we do not overlook, we could answer, limiting ourselves to the area under consideration, by referring to Lord's main and first publication (Lord, 1964) proposing with a well known success, his technique of plication of the vaginalis in the treatment of idiopathic hydroceles in a series of twenty two cases "only".

Additionally, this work does not pretend to present the results of an outcome study using sophisticated and complex statistical methods. It is rather intended to explore, for the first time as far as we could find in the literature and from many discussions over the years, the potential usefulness of a simple classification based on the main clinical features of hydroceles. Our results indicate that the relationship between the clinical presentation of hydroceles (their size and their association with a penis burial in particular), the surgical approach and the management of the patients, deserves attention and is worth exploring further through studies using a proper design.

Finally, due to the recent completion of the visits in areas distant from each other, we cannot yet report on medium and long term outcomes and we are well aware of this limitation. About twenty patients only were reviewed in the second postoperative month. All had very encouraging results and all patients were very satisfied. This gap on the important point of the medium and long term follow up is partially filled by the monitoring by the local nurses and by the nurse

practitioner who is continuing his programme of active detection of hydrocele cases. Additionally the modern communication tools, allow a distant follow up including by pictures, even if not ideal. All patients will be reviewed by the same team during the next mission and the follow up results will then be presented.

A clinical classification of hydroceles based on *Stage* and *Grade* seems useful for the management of patients suffering from hydroceles in filarial endemic countries. An international classification system is also a necessary tool to harmonize the language used, thus allowing fair and valid comparisons at international level. We propose:

- A simple clinical classification of hydroceles in filarial endemic countries based on the *Stage* of enlargement of the scrotum and on the *Grade* of penis burial to guide their surgical management. It would allow a standardized description of hydroceles and the gathering of homogenous international statistics to guide national programmes. This classification is also easily applicable to peno-scrotal lymphoedema.
- A decision tree for the management of hydrocele in filarial endemic countries to be field-tested, completing the 2002 WHO "Algorithm for management of scrotal swelling".

*Acknowledgements.* We wish to especially thank Dr Neil Sharma, Minister of Health of the Fiji Islands, who provided his full and strong support for our two visits. We also want to thank the members of the mobile surgical team and the medical officers of Rakiraki, Taveuni, Levuka and Korovu Hospitals and their teams. We would like to thank and acknowledge here the strong partnership between the Ministry of Health of Fiji, the French Embassy in Fiji (H.E Michel Monnier and M. Denis Decraene, Cooperation and Cultural Action Counselor in particular), the Pacific Leprosy Foundation (M. Michael Gousmett and Mrs Jill Tomlinson in particular) and the World Health Organization.

## REFERENCES

- Addis, D. & Brady, M. (2007). Morbidity management in the Global Programme to Eliminate Lymphatic Filariasis: a review of the scientific literature. *Filaria Journal* **6**: 2.
- Ahorlu, C., Dunyo, S., Asamoah, G. & Simonsen, P. (2001). Consequences of hydrocele and the benefits of hydrocelectomy: a qualitative study in lymphatic filariasis endemic communities on the coast of Ghana. *Acta Tropica* **80**: 215-221.
- Gyapong, J.O., Webber, R.H., Morris, J. & Bennett, S. (1998). Prevalence of hydroceles as a rapid diagnostic index for lymphatic filariasis. *Transaction of the Royal Society of Tropical Medicine and Hygiene* **92**: 40-43.
- Gyapong, M., Gyapong, J., Weiss, M. & Tanner, M. (2000). The burden of hydrocele on men in Northern Ghana. *Acta Tropica* **77**: 287-294.
- Ku, J.H., Kim, M.E., Lee, N.K. & Park, Y.H. (2001). The excisional, plication and internal drainage techniques: a comparison of the results for idiopathic hydrocele. *British Journal of Urology International* **87**: 82-84.
- Lord, P. (1964). A bloodless operation for the radical cure of idiopathic hydrocele. *British Journal of Surgery* **51**: 12.
- Noroës, J. & Dreyer, G. (2010). A Mechanism for Chronic Filarial Hydrocele with Implications for Its Surgical Repair. *PLoS Neglected Tropical Diseases* **4**(6): e695.
- Ortenberg, J., Collins, S. & Roth, C. (2009). Pediatric hydrocele and hernia surgery. <http://emedicine.medscape.com/article/1015147> Updated Sep 21, 2009. Accessed Feb 17, 2011.
- Shah, P.A., Dewoolkar, V.V. & Changlani, T.T. (1992). Ambulatory hydrocele surgery: a review of 50 cases. *Journal of the Royal College of Surgeons of Edinburgh* **37**: 385-386.
- Thomas, G., Richards, F.O. Jr, Eigege, A., Dakum, N.K., Azzuwut, M.P., Sarki, J., Gontor, I., Abimiku, J., Ogah, G., Jindau, M.Y., Jiya, J.Y. & Miri, E.S. (2009). A pilot program of mass surgery weeks for treatment of hydrocele due to lymphatic filariasis in Central Nigeria. *American Journal of Tropical Medicine and Hygiene* **80**(3): 447-451.
- World Health Organization. (2003). Report of an informal consultation on « Surgical approaches to the urogenital manifestations of lymphatic filariasis », 15-16 April 2002. Global Programme for the Elimination of Lymphatic Filariasis. WHO/CDS/CPE/CEE/2002.33. WHO Geneva 2002.
- World Health Organization. (2010). Lymphatic Filariasis Progress report 2000-2009. Strategic plan 2010-2020. WHO Geneva 2010.
- World Health Organization. (2011). First Workshop on Lymphatic Filariasis and other Helminthiases for Pacific Programme Managers 9-12 November 2009, Port Moresby, Papua new Guinea. WHO/WPRO Manila 2011.