

First record in South Asia of deer throat bot fly larvae *Pharyngomyia picta* (Meigen, 1824) (Diptera: Oesteridae) from Sambar deer (*Rusa unicolor*), a new host record

Sreejith Radhakrishnan¹, Ajithkumar, K.G.^{2*}, Reghu Ravindran² and Kavitha Rajagopal³

¹Periyar Tiger Reserve, Thekkady, Kerala, 685 536, India

²Department of Veterinary Parasitology, College of Veterinary and Animal Sciences, Pookode, Wayanad, Kerala, 673576, India

³Mobile Farm Aid Unit, Thariyode, Wayanad, 673121 Kerala, India

*Corresponding author email: ajithkumarkg@gmail.com

Received 23 January 2012; received in revised form 27 February 2012; accepted 6 March 2012

Abstract. The Bot fly larvae, identified to be the third instars of the deer throat bot fly *Pharyngomyia picta* were recovered from the lumen of trachea and secondary bronchi during the necropsy of a female sambar deer (*Rusa unicolor*) in Kerala, India. This forms the first report of *P. picta* from India and the whole of South Asia. Sambar deer is a new host record for the larvae of this fly. Morphological description of the third stage larvae with supporting figures are presented.

INTRODUCTION

Pharyngomyia picta (Diptera: Oesteridae) commonly known as deer throat bot fly has been reported only from the Europe and central Asia (Colwell, 2001). Like all Oesterid flies, only larval stage of *P. picta* is parasitic. Viviparous female flies deposit or forcibly eject packets of larvae on to the muzzle of the host often without landing. Larval stages of *P. picta* are obligate parasites inhabiting nasopharyngeal region of a variety of cervids like red deer (*Cervus elaphus*), sika deer (*Cervus nippon*), roe deer (*Capreolus capreolus*), fallow deer (*Dama dama*) and elk (*Alces alces*) (Ruiz *et al.*, 1993; Colwell, 2001; Soler Cruz, 2008) in the Holarctic region. Oersterid flies reported from Indian sub-continent include those under the genera *Hypoderma*, *Oestrus*, *Gastrophilus*, *Cephalospis*, *Cobboldia*, *Rhinoestrus* and *Gyrostigma* (Sen & Fletcher, 1962).

Rusa unicolor (Kerr, 1792), or sambar, is the largest oriental deer. Seven subspecies occur in varied habitats and elevations in

India, Sri Lanka and throughout southeastern Asia (Leslie, 2011). Forty species of ectoparasites (35 tick species, 2 sucking lice, 2 keds, and 1 flea) have been reported in native, feral, and captive populations of *R. unicolor* (Presidente, 1984). However, no records exist of infestation with *P. picta* larvae in sambar deer in their native range or within introduced habitats with a high prevalence of these flies. Hence, the present communication forms the first report of the occurrence of third larval instars of *P. picta* from India and particularly, in a new cervid host, the sambar deer (*Rusa unicolor*).

MATERIALS AND METHODS

In 2011, a free ranging adult female Sambar deer was found dead at the Kokkara section of Thekkady range of Periyar Tiger Reserve, Thekkady, Kerala, India (N 9° 36' 6", E 077° 10' 32.6"). On necropsy, conducted approximately 36-40 hours postmortem, up to 15 thick 2.5-3 cm long fly larvae (maggots)

with spinous cuticle were recovered from locations within the tracheal lumen and secondary bronchi.

The larvae were collected in 70 per cent ethanol and transported to Department of Veterinary Parasitology, College of Veterinary and Animal Sciences, Pookode for identification. The gross morphology of the maggots was studied under a stereomicroscope without clearing the specimens. Then, they were cleared in 10 per cent Potassium hydroxide solution for 10 minutes. The specimens were then washed with water, dehydrated in ascending grades of alcohol and cleared in creosote for identification. Spiracular plates were dissected out and mounted separately. Identification was based on the keys and descriptions of characteristic morphological features (Zumpt, 1965; Gil Collado, 1984; Grunin, 1989; Colwell, 2001, 2006; Pape, 2001).

Voucher specimens of the larvae were deposited in the Department of Veterinary Parasitology parasite collections.

RESULTS

On necropsy of the sambar deer, both lungs were uniformly dark red, wet and swollen, suggestive of diffuse pulmonary congestion and oedema. Random, focal, creamy white, raised patches, not extending into deeper tissue layers, were observed on the parietal surface of lungs. Other significant finding included diffuse hepatic necrosis, epicardial suffusions, renal capsular adhesion and medullary congestion.

All the robust maggots recovered from trachea and secondary bronchi of the sambar deer were third larval instars. The specimens ranged in length from 25-33mm and in width from 6-7 mm and were identified as *Pharyngomyia picta* (Meigen, 1824).

The larvae were slightly dorsoventrally flattened with well defined spines concentrated on the anterior part of the segments in more or less irregular rows (3-5 rows) on the dorsal surface, except on the last two segments (2-3 rows). However, on the last segment, two rows of spines were observed on the posterior margin (Fig. 1a).

Fairly more number of regular rows (6-8 rows) of spines was seen on the ventral surface than dorsally (Fig. 1b). Characteristic chitinised cuticular hood-like structures covered both anterior spiracles giving the false impression that these third instars possessed eyes (Fig. 1c). Antenomaxillary lobes (Antennal lobes) were widely separated at the base (Fig. 1d). Distinct dark brown spots were present on the posterior aspect of the last segment of these third instars just above the two broad, flat, porous crescent shaped posterior spiracular plates (Fig. 1e). Distance between the peritremes of spiracular plate was 260µm. The concave side of the peritreme was directed lateroventrally (Fig. 1f).

DISCUSSION

Bot fly larvae reported from the nasopharyngeal region of cervids include, those belonging to the genus *Cephenemyia* and *Pharyngomyia* (Angulo-Valadez *et al.*, 2010). Oesterid fly species so far reported from India belong to genera *Hypoderma*, *Oestrus*, *Gastrophilus*, *Cephalopsis*, *Cobboldia*, *Rhinoestrus* and *Gyrostigma* (Sen & Fletcher, 1962). Two species of *Pharyngomyia* viz. *P. picta* and *P. dzerenae* were reported previously. *P. picta* was reported from Europe and central Asia in cervids, whereas the later species has been reported only in Mongolian gazelle (*Gazelle gutturosa*) (Zumpt, 1965; Colwell, 2001, 2006). The characteristic shape of the posterior peritremes and widely separated antenomaxillary lobes of larvae differentiate the third instar of *P. picta* from that of *Cephenemyia* and *P. dzerenae*. Reviews and reports of parasitism in sambar deer in southeast Asia, Australia, USA and India by Presidente (1984), Davidson *et al.* (1987), Eswaran *et al.* (2002) and Ravindran *et al.* (2011) have not recorded the occurrence of *P. picta* in this species. Peritremes of *P. picta* were crescent shaped with its concave side directed latero-ventrally. Each segment of *P. picta* did not show any dark transverse band dorsally. However, the third stage larvae of *Oestrus ovis*, the common nasal bot fly seen

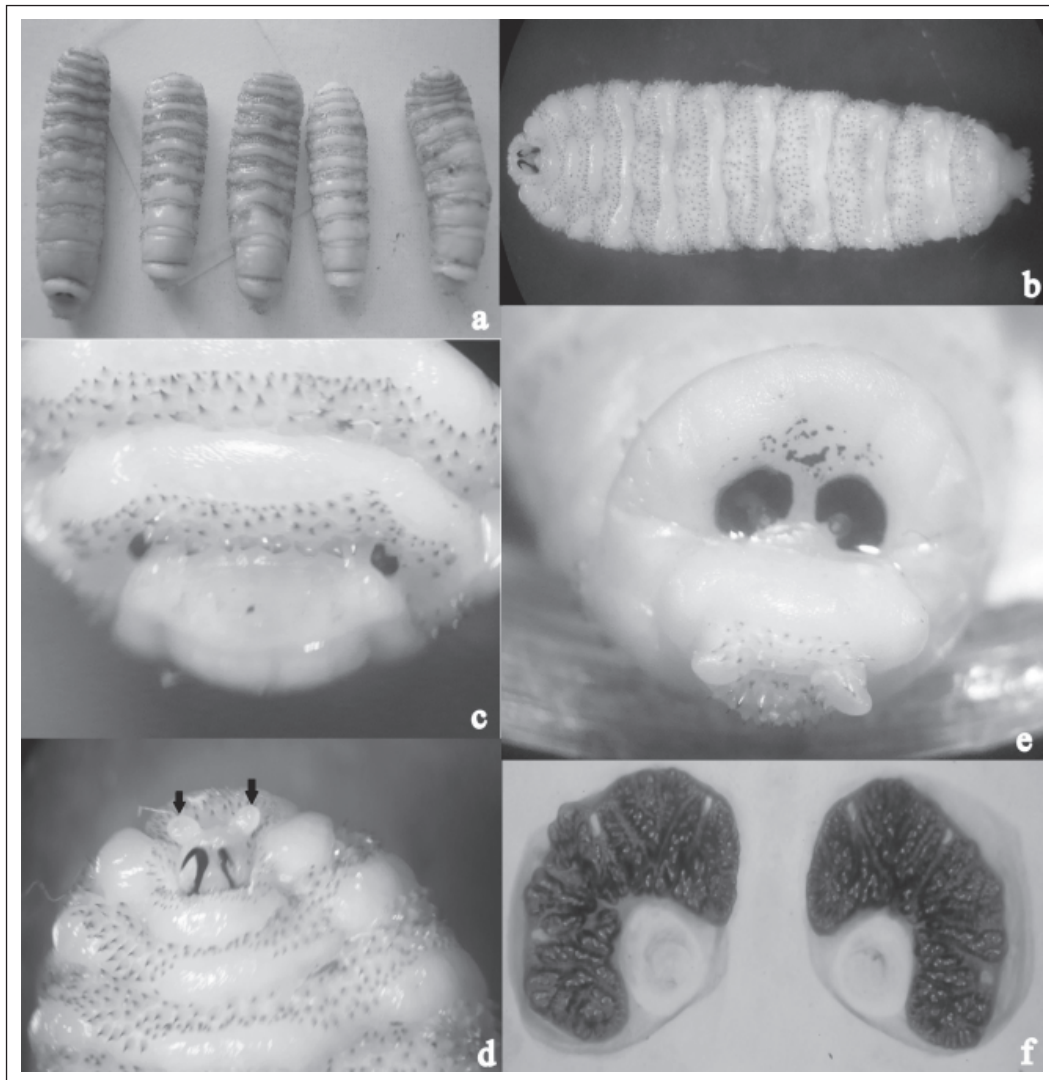


Figure 1. Third stage larvae of *P. picta* (a) Dorsal surface showing well defined spines concentrated on the anterior part of the segments in more or less irregular rows (3-5 rows) except on the last two segments (2-3 rows) (b) Ventral surface showing 6-8 numbers of regular rows of spines on the anterior part of each segments (c) Anterior end (Dorsal view) – Chitinised cuticular hood-like structures covering the anterior spiracles (d) Anterior end (Ventral view) – widely separated antennomaxillary lobes (arrows) at the base (e) Posterior end showing two broad, flat, porous crescents shaped posterior spiracular plates and distinct dark brown spots; (e) Cleared posterior spiracular plates

in the same region, possess dark transverse band dorsally on each segment. Also, the posterior peritremes of *O. ovis* are circular with a central button. Hence, the present communication thus forms the first report of third instar of *P. picta* from South Asia.

The predilection site of third instar of *P. picta* is the nasopharyngeal region predominantly being attached to the mucosa

of pharynx and larynx (Colwell, 2006). According to Drozd (1961), the first instars of these flies are injected into the nostrils of deer, and these rapidly migrate directly to the trachea and then to the lungs. Within the lungs larval growth occurs gradually throughout the winter period, after which there is a phase of rapid growth of first instar. Following this, larvae leave the lungs and

migrate upwards through the trachea towards head, to moult into II and III instars. The present finding of third instars in the trachea may be attributed to the downward migration of III instar from the nasopharynx towards the trachea because of the time lapse between death and conduct of necropsy. A similar case was reported by Sugar (1974), where in migration of first instars from nasopharynx towards trachea and bronchi occurred immediately after death.

In a recent study conducted in a population of Iberian red deer (*Cervus elaphus hispanicus*) by Vicente *et al.*, 2004, the parasitic load of *P. picta* was found high at calf and sub-adult stages which declined thereafter. Prevalence and abundance were more in male hosts compared to female (Bueno-de la Fuente *et al.*, 1998; Vicente *et al.*, 2004). However, Davidson *et al.* (1987) reported that sambar deer had relatively few parasites, higher physical condition rating, less evidence of infectious diseases and generally appeared to be in better general health compared to White-tailed deer.

P. picta is univoltine, with adult flies active from June to August in central and western Europe (Seguy, 1928; Drozd, 1961; Colwell *et al.*, 2006) where the prevalence of this fly was reported. Pupal development period is 21-40 days (Colwell *et al.*, 2006). Hence, the occurrence of fully mature third instars in trachea of sambar deer during July indicates adult fly activity in this region during the same period. However de la Fuente *et al.* (2000) had reported two generation of this fly per year from Spain. This necessitates further intensive prevalence studies of larvae of this fly in sambar deer in this region during postmortem as hunting is banned in India. Such prevalence studies can establish the number of generation per year in this tropical region.

The present communication reports the occurrence of third instar of *P. picta* for the first time from India. The presence of this species in India represents a range extension for this species which was not known to occur in any part of the south Asia. *Rusa unicorn* (sambar deer) is a new host record for the nasopharyngeal bot fly, *P. picta*.

Acknowledgements. The authors thank Dr. David M. Leslie, Jr., Unit Leader and Adjunct Professor, Oklahoma Cooperative Fish and Wildlife Research Unit, Department of Natural Resource Ecology and Management, Oklahoma State University, Professor Arne C. Nilssen, Zoology Department, Tromsø Museum, University of Tromsø, Norway, Dr. Jesus M Perez, Department of Animal biology, Vegetable Biology and Ecology, University of Jaén and Profesor Dr. D. Christian Gortázar Schmidt, Head, National Wildlife Research Institute (IREC), University of Castilla-La Mancha, Ciudad Real, Spain and Dr. Concepcion de la Fuente, Departamento de Patología Animal I (Sanidad Animal), Facultad de Veterinaria, Universidad Complutense de Madrid, for their kind provision of reprints of publications.

REFERENCES

- Angulo-Valadez, C.E., Scholl, P.J., Cepeda-Palacios, R., Jacquet, P. & Dorchie, P. (2010). Nasal bots... a fascinating world!. *Veterinary Parasitology* **174**: 19-25.
- Bueno-de la Fuente, M.L., Moreno, V., Pérez, J.M., Ruiz-Martinez, I. & Soriguer, R.C. (1998). Oestrosis in red deer from Spain. *Journal of Wildlife Diseases* **34**: 820-824.
- Colwell, D.D. (2001). Bot flies and warble flies (Order Diptera: Family Oestridae). In: Samuel, W.M., Pybus, M.J., Kocan, A.A., (Eds) *Parasitic diseases of wild mammals*, (2nd Edn), Iowa State University Press, Iowa, pp. 46.
- Colwell, D.D., Hall, M.J.R. & Scholl, P.J. (2006). The oestrid flies: biology, host-parasite relationships, impact and management. Wallingford, CAB International, pp. 240-242.
- Davidson, W.R., Blue, J.L., Flynn, L.B., Shea, S.M., Marchinton, R.L. & Lewis, J.A. (1987). Parasites, diseases and health status of sympatric populations of sambar deer and white-tailed deer in Florida. *Journal of Wildlife Diseases* **23**: 267-272.

- de la Fuente, C., San Miguel, J.M., Santín, M., Alunda, J.M., Domínguez, I., López, A., Carballo, M. & González, A. (2000). Pharyngeal bot flies in *Cervus elaphus* in central Spain: prevalence and population dynamics. *Journal of Parasitology* **86**: 33-37.
- Drozd, J. (1961). New data from biology of *Pharyngomyia picta* Meigen larvae (Diptera: Oestridae) a *Cervus elaphus* parasite. *Wiadomosci Parazytologiczne* **7**: 373-379.
- Eswaran, K.R., Ravindran, R. & Pillai, K.M. (2002). Parasitic infection of some wild animals at Thekkady in Kerala. *Zoos' Print* **18**: 1030.
- Gil Collado, J., Valls, J.L. & Fierro, Y. (1984). Hallazgo en España de *Cephenemyia auribarbis* (Meigen) (Diptera, Oestridae) [Discovery in Spain of *Cephenemyia auribarbis* (Meigen) (Diptera, Oestridae) (in Spanish)]. *Revista Ibérica de Parasitología* **44**: 463-464.
- Grunin, K.Ya. (1989). Family Oestridae In: Bei-Benko, GI [Translated by Br. Sharma] (ed) *Keys to The Insects of The European Part of The USSR*. Volume 5, Leiden, E.J. Brill Publishing Company. p1233.
- Leslie, D.M. Jr. (2011). *Rusa unicolor* (Artiodactyla: Cervidae). *Mammalian Species* **43**: 1-30.
- Pape, T. (2001). Phylogeny of Oestridae (Insecta: Diptera). *Systematic Entomology* **26**: 133-171.
- Presidente, P.J.A. (1984). Ectoparasites, endoparasites and some diseases reported from sambar deer throughout its native range and in Australia and New Zealand. In: Proceedings of Refresher Course for Veterinarians, University of Sydney, Sydney, Australia, **72**: 543-557.
- Ravindran, R., Ajith Kumar, K.G. & Gafoor, V.M.A. (2011). Parasitic infections in wild animals of Kerala. *Zoos's print* **26**: 34.
- Ruiz, I., Soriguer, R.C. & Perez, J.M. (1993). Pharyngeal bot flies (Oestridae) from sympatric wild cervids in southern Spain. *Journal of Parasitology* **79**: 623-626.
- Seguy, E. (1928). Etude sur les mouches parasites. I. Conopides, Oestrides et Calliphorines de l'Europe occidentale [Study on the parasitic flies. I. Conopides, Oestrides and Calliphorines of western Europe (in French)] Paul Lechevalier, Paris, France, pp 240.
- Sen, S.K. & Fletcher, T.B. (1962). *Veterinary Entomology and Acarology for India*, ICAR, New Delhi, p 668.
- Soler Cruz, M.D. (2008). Myiasis. In: Capinera JL (Ed) *Encyclopedia of Entomology*, (2nd Edn), Dordrecht, Netherlands, Springer, pp 2517-2527.
- Sugár, L. (1974). The occurrence of nasal-throat bot flies (Oestridae) in wild ruminants in Hungary. *Parasitologia Hungarica* **7**: 181-189.
- Vicente, J., Fierro, Y., Martínez, M. & Gortázar, C. (2004). Long-term epidemiology, effect on body condition and interspecific interactions of concomitant infection by nasopharyngeal bot fly larvae (*Cephenemyia auribarbis* and *Pharyngomyia picta*, Oestridae) in a population of Iberian red deer (*Cervus elaphus hispanicus*). *Parasitology* **129**: 349-361.
- Zumpt, F. (1965). *Myiasis in man and animals in the Old World*. Butterworths, London, p267.